

Well-circumscribed infiltrating lipoma of the parotid gland

Fei Chen*, Dan Lu*, Hui Yang, Qi Jun Chen¹

Departments of Otorhinolaryngology, Head and Neck Surgery and ¹Pathology, West China Hospital, Sichuan University, Chengdu, Sichuan, China

*These authors contributed equally to this work

Abstract

Infiltrating lipoma is an uncommon benign mesenchymal tumor that characteristically infiltrates adjacent tissues and tends to recur after excision. This type of lipoma is extremely rare in the head and neck area. We report a rare case of a well-defined infiltrating lipoma of the parotid gland in a 34-year-old man. Physical examination revealed a 2.0 cm in diameter soft mass in upper superficial lobe of the left parotid gland. Ultrasonography showed a weak echo mass with a well-defined margin, which was resected by partial parotidectomy with preservation of the facial nerve. Histology revealed an infiltrating lipoma with well-encapsulated parotid gland. In conclusion, infiltrating lipoma should be considered in the differential diagnosis of soft parotid gland mass.

Key words: Infiltrating lipoma, intramuscular lipoma, lipoma, parotid gland, surgery, therapy

Received: 26th July, 2014; Revised: 20th September, 2014; Accepted: 25th October, 2014


INTRODUCTION

Infiltrating lipomas are more generally found on the trunk and limbs, they are uncommon in the head and neck region. We know of the rare description of a well-circumscribed infiltrating lipoma arising from the parotid gland. The purpose of this paper is to present a case of a single and well-encapsulated infiltrating lipoma in the parotid gland that was treated by partial parotidectomy with preservation of the facial nerve, and the patient had recovered well with a good result.

CASE REPORT

A 34-year-old male patient visited our clinic in May 2011 with a slow-growing, painless mass with a 1-year history located in the left parotid region. Due to the absence of

pain and other symptoms, he was not initially alarmed, but the mass had been increasing in size over a period of 6-month. His past, family and medical histories were not contributory. Physical examination revealed a 2.0 cm × 1.0 cm nonpulsatile, soft, mobile mass in the left parotid area, his facial nerve functions were normal, and the surface of the skin was not tender and was of normal color. His blood biochemistry parameters were within the normal limits. Ultrasonographic (USG) examination showed a weak echo mass within the left parotid gland with well-defined 2.0 cm × 1.0 cm × 3.0 cm mass, and there was no clinical evidence of enlargement of the cervical nodes [Figure 1], suggesting a lipoma as the probable diagnosis. A partial parotidectomy with preservation of the facial nerve was performed. During the surgery, a well-encapsulated mass was found mostly in the upper superficial lobe of the left parotid gland, and a small part of mass invaded in deep lobes of the parotid gland. The mass was separated easily from the parotid gland tissue and facial nerve. On the gross examination, the mass had a fatty yellow appearance and a defined capsule, measured 2.0 cm in diameter. Histopathology showed mature fat cells infiltrating the parotid gland tissue [Figure 2a], and there was a completed fibrous capsule covering the tumor [Figure 2b]. On the basis of the clinical and histopathologic findings, an intramuscular lipoma of the parotid gland was diagnosed. Postoperatively, the patient

Access this article online	
Quick Response Code:	Website: www.ijcep.org
	DOI: 10.4103/2348-8093.149775

Address for correspondence: Dr. Hui Yang, Department of Otorhinolaryngology, Head and Neck Surgery, West China Hospital, Sichuan University, No. 37 Guo Xue Xiang, Wu Hou District, Chengdu, Sichuan, China. E-mail: yh8806@163.com

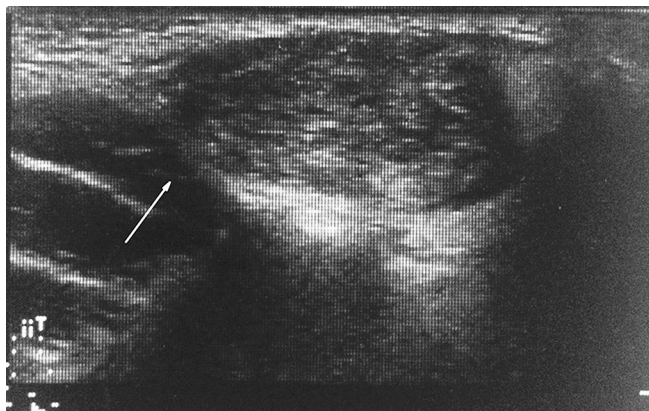


Figure 1: Ultrasonographic showed a weak echo mass, measuring 2.0 cm in diameter, located below the in upper superficial lobe of the left parotid gland. The mass had a well-defined margin (white arrow)

made a complete recovery with no evidence of recurrence at the 31-month follow-up visit.

DISCUSSION

Infiltrating lipoma is a subgroup of lipomas, unlike the other lipomas, is not encapsulated, extensively involving the deep soft tissues, muscle, nerve, or synovium.^[1] The first convincing report of infiltrating lipoma was by Hoffman in 1941, but it was Regan who defined this entity in 1946. It is unusual and exceedingly rare in the head and neck area, it always observed in adults over 40 years of age, males and females are usually affected equally.^[2] Especially, infiltrating lipoma with well-defined involvement with the deep parotid lobe is extremely rare. Similar to lipomas in other part of the body, an asymptomatic mass was the most common clinical symptom, and they tend to grow slowly.^[3]

The pathogenesis of infiltrating lipoma is unclear, local growth of adipose tissue and obesity may be responsible for the formation of lipomas.^[4] Trauma, chronic irradiation, muscular metaplasia, and congenital development are other suggested causes.^[5] Our patient was 171 cm tall and weighed 63 kg. He had never been injured in his parotid gland area, and there were no precipitating factors or activities to explain its occurrence in the parotid gland.

Clinical examination alone is insufficient to identify the nature and location of parotid gland masses. Hence, imaging examination such as USG, computed tomography (CT) or magnetic resonance imaging (MRI) may be helpful in the assessment and diagnosis. Compared with CT and MRI, USG is quick, easy and the least costly, and it has been used as the first-line modality for evaluating head and neck soft tissue masses.^[6] However, the soft tissue characterization is less specific with USG than with CT or MRI, it cannot delineate the real extent of the lesion.

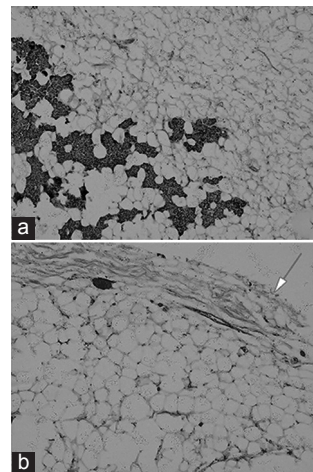


Figure 2: Macroscopic appearance of the infiltrating lipoma (a) showed mature fat cells infiltrating the parotid gland tissue (H and E, ×100) (b) showed a fibrous capsule covering the tumor (white arrow) (H and E, ×100)

But in our case, the USG showed a well-defined mass within the left parotid gland, the size and border were very clear, so we did not perform CT and MRI. A biopsy is always needed to establish the diagnosis of lipoma. In the vast majority of cases, the histopathologic examination shows nonencapsulated proliferation of mature adipose tissue surrounded by an extensive capillary network. However, in our case, histopathology showed mature fat cells infiltrating the parotid gland tissue, and there was a completed fibrous capsule covering the tumor.

Because of the infiltrating nature of the lesion and a high propensity for recurrence, the most important differential diagnosis of intramuscular lipoma is the well-differentiated liposarcoma. Other differential diagnosis of the neck mass should be included with hematoma, cystic hygroma, metastatic carcinoma, and metastatic sarcoma.^[5] Recently, the techniques of chromosome analysis, fluorescence *in situ* hybridization, and molecular assays are expected to be helpful to dramatically improve the understanding and differential diagnosis of adipose tissue tumors.

The treatment of choice is total excision. However, complete excision is usually difficult because these tumors infiltrate muscles or near nerves or vessels. Possible postoperative morbidities, such as facial nerve dysfunction, facial scar or asymmetric contour, and Frey's syndrome must be explained to the patient before operation. However, in our case, the mass was separated easily from the parotid gland tissue and facial nerves, the patient did not incur any of the above-mentioned complications after surgery.

Although the tumors are benign, the rate of recurrence is very high after surgical excision. The recurrence rate

was reported between 3% and 62.5%.^[7] The propensity for recurrence is probably due to the infiltrative nature of this type of tumor and the great difficulty in achieving a complete surgical excision. Su *et al.*^[8] believe that careful preoperative evaluation and complete tumor excision with clear margins are most important to ensure successful surgical results. No case of infiltrating lipoma undergoing malignant changes has been reported in the literature.^[9] In our case, patient had fully recovered with no recurrence after a 31-month follow-up period.

Infiltrating lipoma of the parotid gland with well-circumscribed mass is a rare benign condition with no age or gender predilection. Infiltrating lipoma should be considered in the differential diagnosis of soft parotid gland mass.

REFERENCES

1. Piattelli A, Fioroni M, Rubini C. Intramuscular lipoma of the cheek: A case report. *J Oral Maxillofac Surg* 2000;58:817-9.
2. Couto RA, Mulliken JB, Padwa BL, Hassanein AH, Rogers GF, Kulungowski AM, *et al.* Facial infiltrating lipomatosis: Expression of angiogenic and vasculogenic factors. *J Craniofac Surg* 2011;22:2405-8.
3. Ulku CH, Uyar Y, Unaldi D. Management of lipomas arising from deep lobe of the parotid gland. *Auris Nasus Larynx* 2005;32:49-53.
4. Song HJ, Hong WK, Lee HS, Shin JH, Choi GS. Intramuscular lipoma of the sternocleidomastoid muscle. *J Eur Acad Dermatol Venereol* 2008;22:363-4.
5. Ozcan C, Görür K, Talas D, Aydin O. Intramuscular benign lipoma of the sternocleidomastoid muscle: A rare cause of neck mass. *Eur Arch Otorhinolaryngol* 2005;262:148-50.
6. Gritzmann N, Hollerweger A, Macheiner P, Rettenbacher T. Sonography of soft tissue masses of the neck. *J Clin Ultrasound* 2002;30:356-73.
7. Moumoulidis I, Durvasula P, Jani P. Well-circumscribed intramuscular lipoma of the sternocleidomastoid muscle. *Auris Nasus Larynx* 2004;31:283-5.
8. Su CH, Hung JK, Chang IL. Surgical treatment of intramuscular, infiltrating lipoma. *Int Surg* 2011;96:56-9.
9. Görken C, Alper M, Bilkay U, Celik N, Songür E. Congenital infiltrating lipomatosis of the face. *J Craniofac Surg* 1999;10:365-8.

How to cite this article: Chen F, Lu D, Yang H, Chen QJ. Well-circumscribed infiltrating lipoma of the parotid gland. *Int J Clin Exp Physiol* 2014;1:314-6.

Source of Support: Nil, **Conflict of Interest:** Nil.