

# Protective effect of Vitamin E ( $\alpha$ -tocopherol) on nickel-induced alteration of testicular pathophysiology in alloxan-treated diabetic rats

Jameel Gulab Jargar, Saeed Yendigeri<sup>1</sup>, Salim Abbasali Dhundasi, Kusal Kanti Das<sup>2</sup>

Departments of Physiology and <sup>1</sup>Pathology, Al-Ameen Medical College, Bijapur, Karnataka, <sup>2</sup>Department of Physiology, BLDE University's Shri B.M. Patil Medical College, Hospital and Research Centre, Vijapura, Bijapur, Karnataka, India

## Abstract

**Background and Aim:** Diabetes mellitus is a global problem associated with increased formation of free radicals and decrease in antioxidant potential. Nickel generates free radicals and induces oxidative and nitrosative stress with depletion of antioxidants. Vitamin E is the most effective chain-breaking antioxidant against lipid peroxidation. Therefore, the present study was intended to evaluate the possible protective effect of Vitamin E ( $\alpha$ -tocopherol) on oxidative stress in the testis of diabetic rats exposed to nickel.

**Methods:** Diabetes was induced by alloxan monohydrate (15 mg/100 g b.wt, i.p.) in adult male Wistar albino rats. Diabetic rats in respective groups were exposed to nickel sulfate (2.0 mg/100 g b.wt, i.p) and  $\alpha$ -tocopherol (10 mg/100 g b.wt, i.m.) alone as well as in combination on alternate days until the tenth doses. Testicular cholesterol and protein, aspartate aminotransferase (AST), alanine aminotransferase (ALT), nitric oxide, and lipid peroxide were evaluated by ultraviolet-visible spectrophotometer. Testicular histopathology was also evaluated.

**Results:** Exposure of diabetes and nickel showed significantly decreased body weight, testicular-somatic index, testicular cholesterol and protein, AST, ALT, nitric oxide, and lipid peroxide levels. Simultaneous  $\alpha$ -tocopherol supplementation showed remarkable improvement in all these alterations. We observed damage in testicular architecture with, tortuous seminiferous tubules, foci of congestion, necrosis, loss of spermatogenesis > 75% and loss of germ cell layer in diabetic and nickel-exposed diabetic rats. Testis of simultaneous  $\alpha$ -tocopherol supplemented diabetic rats showed many normal seminiferous tubules and normal spermatogenesis ( $\geq 50\%$ ).

**Conclusion:** Vitamin E ( $\alpha$ -tocopherol) supplementation could exert a protective effect on the testis of diabetic rats exposed to nickel by suppressing the increased oxidative stress.

**Key words:** Diabetes, nickel, oxidative stress, testicular dysfunction,  $\alpha$ -tocopherol

Received: 10<sup>th</sup> October, 2014; Revised: 21<sup>st</sup> November, 2014; Accepted: 3<sup>rd</sup> December, 2014

## INTRODUCTION

Diabetes mellitus is a global problem associated with increased generation of free radicals and decrease in antioxidant potential, which results in disturbed balance between free radical formation and antioxidant

protection in normal cell. The number of people with diabetes is expected to rise to 592 million by 2035. As of 2014, an estimated 387 million people have diabetes worldwide.<sup>[1]</sup> This is equal to 8.3% of the adult population, with equal rates in both women and men.<sup>[2]</sup> Compared with nondiabetic individuals, male diabetic patients showed an increased incidence of hypogonadism and infertility.<sup>[3]</sup> Both insulin-dependent (type 1) and noninsulin-dependent diabetes (type 2) are associated with increased oxidative stress. Oxidative stress damage is also implicated in the pathogenesis of testicular dysfunction in diabetes.<sup>[4]</sup> Exposure to heavy metal like nickel has been shown impair DNA repair-related enzymes through the production of reactive oxygen species (ROS).<sup>[5]</sup> It has also been shown that nickel

Access this article online	
Quick Response Code:	Website: www.ijcep.org
	DOI: 10.4103/2348-8093.149762

**Address for correspondence:** Dr. Kusal Kanti Das, Department of Physiology, BLDE University's Shri B.M. Patil Medical College, Hospital and Research Centre, Karnataka, India. E-mail: kusaldas@yahoo.com

could increase hepatic glycolysis and pancreatic glucagon release, decrease peripheral utilization of glucose, and induce gluconeogenesis.<sup>[6]</sup> Our previous studies and some other studies have demonstrated that nickel administration induce hyperglycemia in rats.<sup>[7,8]</sup> Extensive use of nickel in various industries (stainless steel, coal-fired power plants, etc.) and occupational exposure of nickel on human beings is definitely a matter of serious impact on human health especially male infertility in diabetic people. Vitamin E is a key lipid-soluble antioxidant and the most effective chain-breaking antioxidant within the cell membrane where it protects membrane fatty acids from lipid peroxidation.<sup>[9]</sup> Vitamin E can transfer its phenolic hydrogen to a peroxy free radical of a peroxidized polyunsaturated fatty acid ( $\omega$ -6 PUFA), thus it break the radical chain reaction and prevent the peroxidation of PUFA in cellular and subcellular membrane phospholipids. Hence, the aim of this study was to evaluate the possible protective effect of Vitamin E ( $\alpha$ -tocopherol) on the testis of diabetic rats exposed to nickel.

## MATERIALS AND METHODS

Adult male Wister albino rats (aged 60–70 days) weighing 180–200 g were fed with laboratory stock diet and water *ad libitum*. Rats were maintained in a 12 h light/12 h dark cycle at constant room temperature ( $22 \pm 4^\circ\text{C}$ ), humidity  $\sim 70\%$ . The acclimatized rats were divided into five groups with six rats in each group. Three rats were kept in each metabolic wire cage (60 cm  $\times$  30 cm  $\times$  20 cm). All the experimental procedures followed were performed in accordance with the approval of the Institutional Animal Ethics Committee under strict compliance of the Committee for the Purpose of Control and Supervision of Experiments on Animals guidelines for the experimental studies.

### Induction of experimental diabetes

The rats were fasted overnight and diabetes was induced with a single intraperitoneal injection (i.p.) of 15% freshly prepared solution of alloxan monohydrate (Sigma-Aldrich, USA) in sterile normal saline, at a dose of 15 mg/100 g of body weight, just before use. Since alloxan is capable of producing fatal hypoglycemia as a result of massive pancreatic insulin release, rats were treated with 20% glucose solution (i.p.) after 6 h. The rats were then kept for the next 24 h on 5% glucose solution bottles in their cages to prevent hypoglycemia.<sup>[10]</sup> After 3 days, blood samples were collected from the tail vein. Serum was separated, and fasting glucose levels were estimated by glucose oxidase-peroxidase enzymatic method<sup>[11]</sup> to confirm diabetes, only those rats which showed  $\geq 250$  mg/dL blood glucose level was selected for the study.

### Experimental groups

Group I and Group II rats served as controls and diabetic, respectively. Treatment with nickel and  $\alpha$ -tocopherol on diabetic rats in Groups III, IV, and V, was started on the 10<sup>th</sup> day of the confirmation of diabetes and was continued on alternate days until the tenth doses. The treatment period was 21 days. Group III diabetic rats were administered nickel sulfate (New India Chemical Enterprises, Kochi, India) in double distilled water, at a dose of 2.0 mg/100 g of body weight, i.p.<sup>[12]</sup> Group IV diabetic rats were supplemented with  $\alpha$ -tocopherol (Merck, Germany) in absolute ethanol, at a dose of 10 mg/100 g of body weight, intramuscular injection (i.m.).<sup>[13]</sup> Group V diabetic rats were given both nickel (i.p.) and  $\alpha$ -tocopherol (i.m.) simultaneously.

### Animal sacrifice and sample collection

At the end of the treatment period, the rats were sacrificed after overnight fasting by cervical decapitation<sup>[14]</sup> between 09.00 a.m. to 11.30 a.m. to avert the circadian influences on the rats as lipid peroxide (an oxidative stress parameters) in our study is sensitive to circadian rhythm. After sacrifice of experimental rats one side of the testis was dissected out, trimmed of fat, wiped clean, and weighed immediately, then was kept in tissue container and stored at  $-20^\circ\text{C}$  for further biochemical analysis.

### Gravimetry

The body weight of all the rats was recorded on the day 1 of treatment (10<sup>th</sup> day after confirmation of diabetes) and the day of sacrifice. The testes weight was determined to the nearest of 0.1 mg in a single pan balance (ATCO. Model D2RS02-W). Further, we calculated testicular-somatic index; it is the ratio of organ weight to body weight of the rat.

### Biochemical parameters in testicular tissue homogenate

#### Cholesterol concentration

The method of Chiamori and Henry<sup>[15]</sup> was used to evaluate testicular cholesterol concentration. It was done using tissue homogenate, acetone: ethanol mixture (1:1), glacial acetic acid (aldehyde free), and color reagent (ferric-ethanol-sulfuric reagent). Tissue homogenate was prepared with 100 mg testis homogenized in 5 mL acetone: ethanol mixture (1:1) using tissue homogenizer (REMI, type RQ-127A) and centrifuged (R-4C, REMI) at 3500 rpm for 15 min. Standard procedure was followed using ultraviolet-visible spectrophotometer (SL 159, Elico Ltd). Optical density was recorded at 570 nm and testicular cholesterol concentration of samples was calculated using the standard curve.

#### Protein level

The method of Lowry *et al.*<sup>[16]</sup> was used to evaluate testicular protein level. Tissue homogenate was prepared

with 50 mg testis homogenized in 10 mL phosphate buffer saline, pH 7.4 using a tissue homogenizer and centrifuged at 3500 rpm for 15 min.

#### *Aspartate transaminase and alanine transaminase activity*

The method of Reitman and Frankel.<sup>[17]</sup> and Tietz.<sup>[18]</sup> was used to evaluate the activities of testicular aspartate aminotransferase (AST) and alanine aminotransferase (ALT). It was done using tissue homogenate, DNPH (2,4-Dinitrophenyl hydrazine), 0.4N NaOH, AST substrate (for AST activity) and ALT substrate (for ALT activity). Optical density of samples was recorded at 505 nm and testicular AST, and ALT activity was calculated.

#### *Nitric oxide level*

The method of Moshage *et al.*<sup>[19]</sup> was used to calculate testicular nitric oxide level. 500 mg of testis was homogenized with 5 ml of normal saline in a tissue homogenizer. To deproteinize the sample, 1 mL homogenate was added with 2 mL of ethanol and centrifuged at 5000 rpm for 20 min. To the supernatant, vanadium (III) chloride was added as a catalyst. Greiss reagent (250  $\mu$ L sulfanilamide), and (250  $\mu$ L N-ethylene diamine dihydrochloride) was added. Standard procedure was followed to record optical density at 540 nm, and the concentration of testicular nitric oxide was calculated.

#### *Lipid peroxide level*

The reaction of lipid peroxides in rat testicular tissues was determined by the method of Ohkawa *et al.*<sup>[20]</sup> Testicular tissue was homogenized with 1.15% KCl (10% w/v) using a homogenizer. The assay mixture consisted of 0.1 mL of tissue homogenate, 0.2 ml of 8.1% SDS, 1.5 ml of 20% acetic acid (adjusted to pH 3.5 with NaOH using Digital pH meter [LI 120, Elico Ltd.]) and 1.5 mL of 0.8% aqueous solution of thiobarbituric acid (TBA). It was heated for 60 min at 95°C (by using Equitron Digital Water Bath). Thereafter, the mixture was cooled and extracted with 5 mL of the mixture of n-butanol and pyridine (15:1, v/v). After centrifugation at 4000 rpm for 10 min, the organic phase was assayed spectrophotometrically at 532 nm. The lipid peroxide levels in testicular tissue were expressed as  $\mu$ mol TBA reactants/g protein.

#### *Histopathological evaluations*

The testes of the experimental rats were dissected out and subjected to histopathological evaluations.<sup>[21]</sup> The microscopic study on routine stain (hematoxylin and eosin stain) was done, and the following changes of the tissues of control and various treated groups were observed; viz. atrophy, degeneration, necrosis, inflammation, tumorigenicity, etc. Photomicrographs

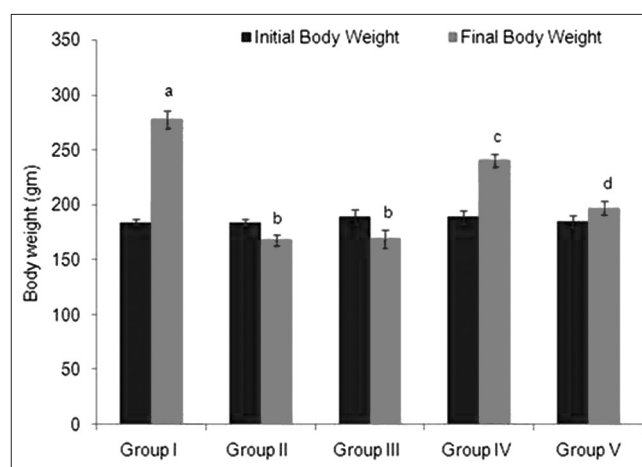
were taken out with the help of personal computer connected Magnifying Image Processing System.

#### **Statistical analysis of the data**

The statistical data obtained from all the control and experimental samples were analyzed for evaluating a range of significance. Results are expressed as mean  $\pm$  standard deviation. To determine the significance of inter-group differences, one-way analysis (ANOVA) followed by Bonferroni *post hoc t*-test were done by using SPSS version 22 (SPSS Software Inc., Chicago, IL, USA).

## **RESULTS**

Diabetic rats (Group II) and nickel-exposed diabetic rats (Group III) showed a significant decrease in final body weight (at the end of the experiment) as compared to their initial body weight (before experiment); but there was a significant elevation observed in final body weight of normal control rats (Group I). We also found that there was no significant change between final body weight of Group II and Group III rats. The final body weight of  $\alpha$ -tocopherol supplemented diabetic rats (Group IV) significantly increased as compared to Group II rats. Simultaneous  $\alpha$ -tocopherol supplementation in nickel-exposed diabetic rats (Group V) also shown significant elevated final body weight when compared with Group III rats [Figure 1]. It was also indicated by the percent body weight gain as compared to Group I rats [Table 1]. Group II and Group III rats were shown a significant decrease in testicular weight and testicular somatic index as compared to Group I rats (Group II vs. Group I and Group III vs. Group I). But Group IV versus Group II and Group V versus Group III



**Figure 1:** Effect of  $\alpha$ -tocopherol on nickel-induced alteration in body weight of diabetic rats. Group I - Normal control, Group II - Diabetic control, Group III - Diabetic + nickel, Group IV - Diabetic +  $\alpha$ -tocopherol, Group V - Diabetic + nickel +  $\alpha$ -tocopherol. For final body weight the values with different superscripts (a, b, c, d) were significantly different from each other ( $P < 0.05$ ). For initial body weight, the values are not significant from each other

showed a significant increase in testicular weight and testicular somatic index [Table 1].

As shown in Table 2, testicular cholesterol concentration was increased two-fold in diabetic rats (Group II) and nickel-exposed diabetic rats (Group III) as compared to normal control rats (Group I). On the other hand,  $\alpha$ -tocopherol supplemented diabetic rats (Group IV) and  $\alpha$ -tocopherol supplemented nickel-exposed diabetic rats (Group V) showed significant decrease in testicular cholesterol concentration as compared to Group II and Group III rats. Significant decrease in the testicular protein level observed in both the groups, that is, diabetic (Group II) and nickel-exposed diabetic (Group III), as compared to normal control rats (Group I). Further of  $\alpha$ -tocopherol supplementation in diabetic rats (Group IV) and nickel-exposed diabetic rats (Group V) revealed that there was significant increase in the level of testicular protein as compared with Group II and Group III, respectively (Group IV vs. Group II and Group V vs. Group III) [Table 2]. Diabetic rats (Group II) and nickel-exposed diabetic rats (Group III) showed highly significant increase in the testicular AST and ALT activities when we compared with normal control rats (Group I). On the other hand,  $\alpha$ -tocopherol supplemented diabetic rats (Group IV) and simultaneous nickel-exposed diabetic rats (Group V) showed significant decrease in the AST and ALT activities compared to Group II and Group III, respectively [Table 2]. Our results presented in the Table 2 shows significant increase in the level of testicular nitric oxide in diabetes (Group II) and nickel-exposed

diabetic rats (Group III) as compared to normal control rats (Group I). Also,  $\alpha$ -tocopherol supplemented diabetic (Group IV) and nickel-exposed diabetic (Group V) rats showed significantly decreased nitric oxide level in testes when compared with Group II and Group III respectively. When we compared Group II and Group III rats, we observed that there was significant alteration in nitric oxide level in both groups. Group II (diabetic control) and Group III (diabetic + nickel) rats showed a significant increase in the lipid peroxide level in testes as compared with Group I (normal control) [Table 2]. Rats supplemented with  $\alpha$ -tocopherol (Group IV and Group V) showed a significant decreased in the lipid peroxide level as compared to Group II and Group III, respectively. Interestingly our results showed nonsignificant alterations in testicular protein, AST, ALT, nitric oxide, and lipid peroxide levels when compared to Group II versus Group III. But all parameters were significantly altered with  $\alpha$ -tocopherol supplementation (Group II vs. Group IV and Group III vs. Group V).

Photomicrographs of Group I (control) rats showed normal testicular architecture with normal seminiferous tubules, fibrovascular stroma, and normal process of spermatogenesis [Figure 2]. But photomicrographs of Group II (diabetic control) rats showed an adverse effect on testicular architecture with interstitial fibrosis, basement membrane, and loss of spermatogenesis process [Figure 3]. Whereas, photomicrographs of Group IV ( $\alpha$ -tocopherol supplemented diabetic) rats showed protective role of  $\alpha$ -tocopherol supplementation on distorted testicular structure in

**Table 1:** Effect of  $\alpha$ -tocopherol on nickel-induced alteration in gravimetry of diabetic rats

Parameters	Group I (normal control)	Group II (diabetic control)	Group III (diabetic+nickel)	Group IV (diabetic+ $\alpha$ -tocopherol)	Group V (diabetic+nickel+ $\alpha$ -tocopherol)
Body weight gain (%)	46.81±9.64 <sup>a</sup>	-8.62±1.72 <sup>b</sup>	-10.65±3.69 <sup>b</sup>	27.31±2.06 <sup>c</sup>	6.29±1.62 <sup>d</sup>
Testes weight (g)	1.68±0.09 <sup>a</sup>	0.90±0.04 <sup>b</sup>	0.88±0.04 <sup>b</sup>	1.40±0.04 <sup>c</sup>	1.09±0.03 <sup>d</sup>
Testicular somatic index	0.0061±0.0002 <sup>a</sup>	0.0053±0.0001 <sup>b</sup>	0.0052±0.0001 <sup>b</sup>	0.0058±0.0001 <sup>a</sup>	0.0056±0.0001 <sup>b</sup>

ANOVA: Analysis of variance, SD: Standard deviation. Each value is mean±SD of six observations in each group. In each row, values with different superscripts (a, b, c, d) were significantly different from each other ( $P < 0.05$ ). *Post-hoc t*-test analysis was used to test for differences among the means when ANOVA indicated a significant *P* value

**Table 2:** Effect of  $\alpha$ -tocopherol on nickel-induced alteration in testicular biochemical parameters of diabetic rats

Parameters	Group I (normal control)	Group II (diabetic control)	Group III (diabetic+nickel)	Group IV (diabetic+ $\alpha$ -tocopherol)	Group V (diabetic+nickel+ $\alpha$ -tocopherol)
Testicular cholesterol (mg/g)	22.10±2.67 <sup>a</sup>	44.98±5.79 <sup>b</sup>	51.47±3.52 <sup>c</sup>	35.53±4.83 <sup>d</sup>	42.47±4.33 <sup>b</sup>
Testicular protein (mg/g)	13.07±0.82 <sup>a</sup>	7.04±0.34 <sup>b</sup>	6.85±0.99 <sup>b</sup>	9.97±0.56 <sup>c</sup>	7.94±0.99 <sup>d</sup>
AST (U/mg)	117.71±0.41 <sup>a</sup>	181.88±0.71 <sup>b</sup>	187.51±0.06 <sup>b</sup>	153.96±0.41 <sup>c</sup>	164.38±0.35 <sup>d</sup>
ALT (U/mg)	42.46±6.21 <sup>a</sup>	72.98±4.63 <sup>b</sup>	79.90±4.98 <sup>b</sup>	53.49±5.30 <sup>c</sup>	55.03±6.43 <sup>c</sup>
Nitric oxide (mmole/g)	2.62±0.10 <sup>a</sup>	4.76±0.34 <sup>b</sup>	4.88±0.35 <sup>b</sup>	3.08±0.10 <sup>c</sup>	3.21±0.13 <sup>c</sup>
Lipid peroxide ( $\mu$ mol TBA reactants/g protein)	4.55±0.45 <sup>a</sup>	7.94±0.22 <sup>b</sup>	8.15±0.76 <sup>b</sup>	4.95±0.12 <sup>a</sup>	6.89±0.43 <sup>c</sup>

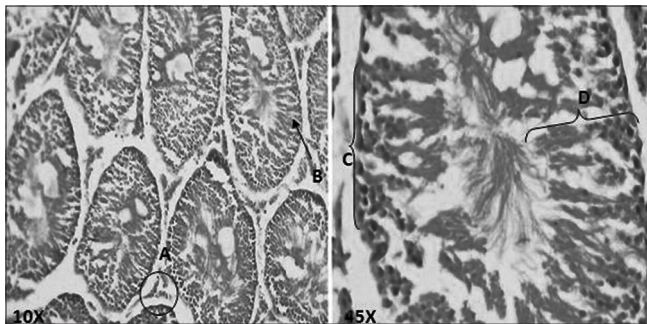
TBA: Thiobarbituric acid, ANOVA: Analysis of variance, AST: Aspartate transaminase, ALT: Alanine transaminase, SD: Standard deviation. Each value is mean±SD of six observations in each group. In each row, values between two groups with different superscripts (a, b, c, d) were significantly different from each other ( $P < 0.05$ ). *Post-hoc t*-test analysis was used to test for differences among the means when ANOVA indicated a significant *P* value

alloxan-treated diabetes by improvement in distorted testicular architecture, interstitial fibrosis, and reduced spermatogenesis process [Figure 4]. Histopathological studies, in Group III (nickel-exposed diabetic) rats, depicted more damage in testicular architecture with diminution in the number and disarrangements in different generation of germ cells, tortuous seminiferous tubules, foci of congestion, necrosis, interstitial fibrosis, marked thickening of tubular lining basement membrane and many foci of loss of spermatogenesis > 75% and loss of germ cell layer [Figure 5]. In Group V ( $\alpha$ -tocopherol supplementation in nickel-exposed diabetic) rats, we observed positive role of  $\alpha$ -tocopherol supplementation on damaged testicular architecture of nickel-exposed diabetic rats. In Group V,  $\alpha$ -tocopherol supplementation showed many normal seminiferous tubules, mild thickening of tubular lining basement membrane, normal spermatogenesis ( $\geq 50\%$ ) with few loss of spermatogenesis, mild increase in germ cell layer [Figure 6].

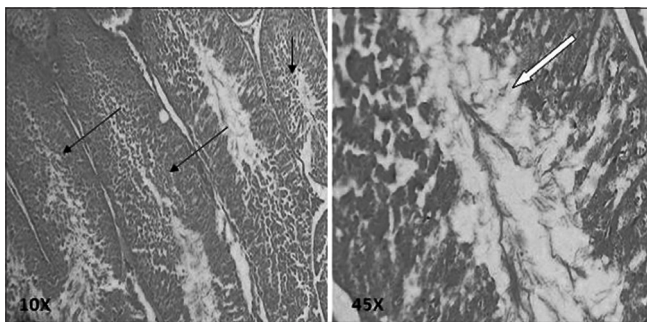
## DISCUSSION

Diabetes represents a privileged situation for oxidative stress exerting harmful effects.<sup>[22]</sup> Decreased body weight is a significant marker of toxicity. Body weight losses observed in our study in diabetic rats as compared with normal control rats may be due to

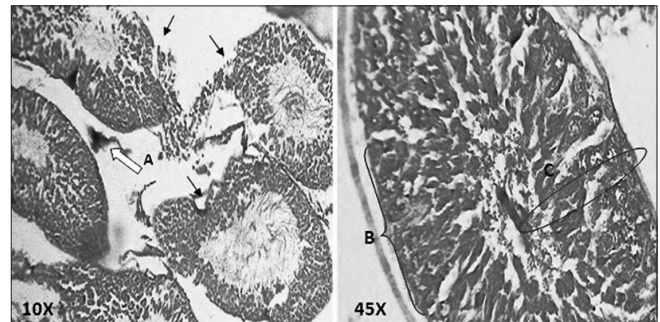
the metabolic derangements, and it could culminate in tissue wasting and breakdown.<sup>[23,24]</sup> According to Vivek *et al.*,<sup>[25]</sup> besides the impairment of islet cells by alloxan, it also has a significant effect on the body weight of the rats. In our previous studies, we observed the nickel has an adverse effect on total body weight gain of rats.<sup>[26]</sup> Simultaneous supplementation with  $\alpha$ -tocopherol has cut down the percent body weight loss of nickel-exposed diabetic rats and showed improvement of body weight which reflects restoration of growth rate among diabetic and nickel-exposed diabetic rats as rats were under its growing phase.<sup>[27]</sup> In our study, a reduction of the weight of testes (gonadal weight) was seen in diabetic control and nickel-exposed diabetic rats could be due to testicular atrophy in diabetic rats. The effects of experimental diabetes on the functions of reproductive system and disturbances of hypothalamus-pituitary-gonadal axis have been reported.<sup>[28]</sup> The present study shows alloxan-treated diabetes resulted in significant diminution in testicular somatic index, which may be due to apoptotic cell death caused by low serum testosterone level as it is the prime regulator of normal growth of male reproductive organs.<sup>[29]</sup> The supplementation of  $\alpha$ -tocopherol in diabetic and nickel-exposed diabetic rats showed a



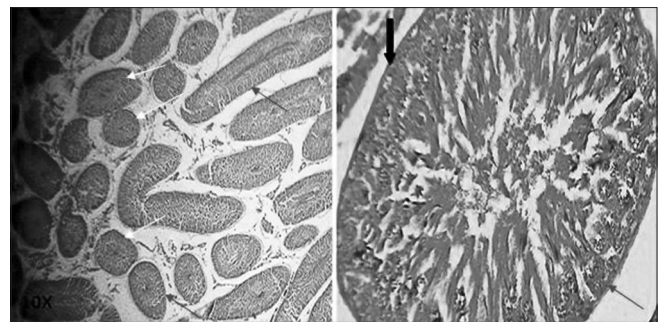
**Figure 2:** Testis section of Group I (normal control) rats. Fibrovascular stroma present between the seminiferous tubules contains the varying number of interstitial cells of Leydig (A), normal seminiferous tubules (B), basement membrane (C) and spermatogenesis process (D)



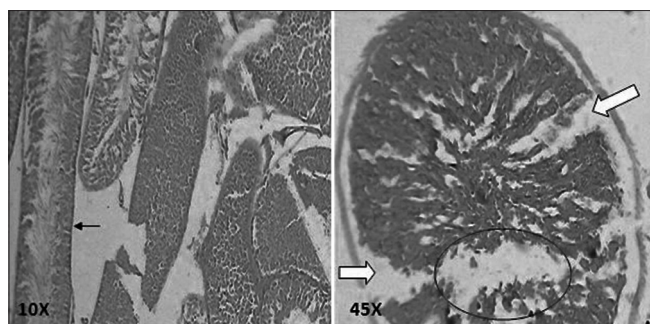
**Figure 4:** Testis section of Group IV (diabetic +  $\alpha$ -tocopherol) rats. Recovery in distorted testicular parenchymal cells (arrows), interstitial fibrosis and also increased spermatogenesis process (block arrow)



**Figure 3:** Testis section of Group II (diabetic control) rats. Distorted testicular parenchymal tissue (black arrow), interstitial fibrosis (A), marked thickening of tubular lining basement membrane (B) and loss of spermatogenesis (C)



**Figure 5:** Testis section of Group III (diabetic + nickel) rats. Diminution in the number and disarrangements in different generation of germ cells (circle), tortuous seminiferous tubules, foci of congestion, necrosis, interstitial fibrosis, marked thickening of tubular lining basement membrane (arrow) and many foci of loss of spermatogenesis >75% and loss of germ cell layers (block arrow)



**Figure 6:** Testis section of Group V (diabetic + nickel +  $\alpha$ -tocopherol) rats. Normal testicular parenchymal architecture maintained (white arrows), majority of seminiferous tubules appear normal, mild thickening of tubular lining basement membrane (red arrows), spermatogenesis appears normal with few loss of spermatogenesis up to 50%, mild increase in germ cell layer (black arrow), mild decrease in number of interstitial foci of cells of Leydig, foci of congestion, edema, and interstitial fibrosis

significant increase in testicular weight and testicular somatic index. Therefore, from the results of the present study it could be suggested that  $\alpha$ -tocopherol has the potential antioxidant property to scavenge free radicals produced by alloxan diabetes and nickel.

It is well-established that diabetes induces the dyslipidemia.<sup>[30]</sup> In the present study, testicular cholesterol concentration was significantly higher in diabetic and nickel-exposed diabetic rats. It indicates a loss of membrane integrity. The present study showed nickel exposure to diabetic rats exhibited oxidative stress in testicular tissue as indicated by further increase in testicular cholesterol level. It may be a result of nickel accumulation in the liver, and this may lead to a disturbance of lipid metabolism and an elevation of testicular cholesterol.<sup>[31]</sup> The lowering of total cholesterol was observed with  $\alpha$ -tocopherol supplementation which indicates that this vitamin specifically targeted the mechanisms involved in diabetes-induced dyslipidemia.

Decreased protein level is observed in our diabetic study group. Advanced oxidative protein products, ROS, and free radicals produce protein carbonyl products are considered as markers of oxygen-mediated protein damage.<sup>[32]</sup> Nickel directly induces alteration of protein synthesis by decreasing total protein concentration in testes. Perhaps nickel induces a protein catabolic pathway also, apart from reduced protein anabolism. Functional support from testicular androgen may be also disturbed by reduced concentration of testicular androgen and its impact on testicular biosynthesis of protein.<sup>[33]</sup> In our present study, antioxidant supplement clearly reflects beneficial role of  $\alpha$ -tocopherol on protein synthesis on diabetes and nickel-exposed diabetic rats.

This study showed the increased activities of AST and ALT in testes, indicated that diabetes may induce

testicular metabolic dysfunction, it is in agreement with the previous studies.<sup>[34]</sup> Leakage of cytoplasmic enzymes appears to be a sensitive indicator of cellular injury produced by heavy metals. Nickel executed the leaked enzymes leading to increase in AST and ALT activity in the testes.<sup>[35,36]</sup> Our present study of nickel-exposed diabetic rats also showed elevated activities of both the enzymes. On the other hand,  $\alpha$ -tocopherol supplementation reduced the alteration of these enzymatic activities possibly by decreasing the leakage in diabetic as well as in nickel-exposed diabetic rats.

In our studies, testicular nitric oxide level was increased in diabetic rats. It may be due to the formation of paired nitrite, destruction of iron-sulfur clusters, thiol nitrosylation and nitrates of protein tyrosine residual. Our results are in agreement with the previous studies.<sup>[37,38]</sup> There is a significant role of antioxidant to counteract or neutralize oxidative free radicals with nitric oxide donors. Vitamin E has the ability to preserve diacylglycerol kinase activity and thus normalize the upregulation in PKC (protein kinase C) which can inhibit nitric oxide synthase (NOS) activity. Our previous studies had shown an elevation of nitric oxide level in nickel-exposed rats.<sup>[39]</sup> It clearly reflects increased inducible NOS (iNOS) activity or increased nitrosative stress by nickel in testes. Our present study of nickel-exposed diabetic rats also showed elevated nitric oxide level. On the other hand, the simultaneous  $\alpha$ -tocopherol supplementation possibly reduced the nitrosative stress in diabetic and nickel-exposed diabetic rats.

The increased lipid peroxidation seen in the testes of nickel-exposed diabetic rats suggests the possible production of superoxide anions, hydroxyl radicals, and singlet oxygen from peroxide ( $H_2O_2$ ) reacting with the nickel sulfate complex of glycylglycyl-L-histidine. Nickel also assists in the generation of activated oxygen species that in turn, can cause damage to lipids, cell membranes, and DNA.<sup>[40]</sup> Nickel, which crosses the blood-testis barrier, has been suggested as the basis of the oxidative stress and eventual oxidative damage seen in testicular tissues.<sup>[41]</sup> In our study, diabetic control (Group V) rats showed a significantly higher concentration of lipid peroxide. These evidences correspond to the findings of an earlier study.<sup>[42]</sup> Increase in lipid peroxide levels in diabetic rat testes may be contributed by increased production of free radical or due to decrease in the antioxidant status. Further, we observed lipid peroxide levels decreased in both diabetic and nickel-exposed diabetic rats after supplementation of  $\alpha$ -tocopherol in Groups IV and V. It may be due to significant protection by  $\alpha$ -tocopherol against oxidative stress in rat testes.

The abnormal spermatogenesis in diabetic conditions was reported in previous studies.<sup>[43]</sup> In this study, the

histological changes of testicular tissue are comparable and in accordance with the studies that reported the degeneration and necrosis of seminiferous tubules, giant cell formation, and interstitial tissue changes.<sup>[44,45]</sup> Nickel can cross the blood testis barrier and make degeneration of seminiferous tubules, focal necrosis and decreases spermatogenesis.<sup>[39]</sup> In our present study, nickel-exposed diabetic rats showed further damage in testicular architecture. Further, we observed supplementation of  $\alpha$ -tocopherol appeared to ameliorate the adverse effects of alloxan diabetes and nickel-exposed diabetes on distorted testicular architecture, interstitial fibrosis, and reduced spermatogenesis process. It may be due to  $\alpha$ -tocopherol is powerful lipophilic antioxidant that is absolutely vital for the maintenance of mammalian spermatogenesis.<sup>[46]</sup> An interesting outcome of this study was not to observe any additional adverse impact of combined effect of diabetes and nickel sulfate as compared to only diabetes or nickel sulfate treatment.

### Limitations of the study

We could not evaluate testicular nickel concentration in the diabetic rats.

### CONCLUSION

Diabetic and nickel-exposed diabetic rats clearly reflected a definite oxidative and nitrosative stress in the physiological system including testicular histopathology of the adult male albino Wistar rats. Nickel-exposed diabetic rats showed nearly same adverse effects as compared to only diabetic rats or nickel alone treated rats. The alteration in oxidative and nitrosative stress markers in testes due to nickel treatment and diabetes or in both clearly indicate changes in testicular microenvironments which is further supported by altered histopathology of testes. Further, in our study, the simultaneous  $\alpha$ -tocopherol supplementation showed a protective effect on alloxan-treated diabetes and nickel-exposed diabetes by attenuating oxidative stress in testicular pathophysiology. This makes us conclude that possible consideration of  $\alpha$ -tocopherol supplementation as a preventive measure to combat heavy metal toxicities and diabetes mellitus.

### REFERENCES

1. IDF. International Diabetes Federation. Update 2014. [Last retrieved on 2014 Nov 29].
2. Shi Y, Hu FB. The global implications of diabetes and cancer. *Lancet* 2014;383:1947-8.
3. Tang XY, Zhang Q, Dai DZ, Ying HJ, Wang QJ, Dai Y. Effects of strontium fructose 1,6-diphosphate on expression of apoptosis-related genes and oxidative stress in testes of diabetic rats. *Int J Urol* 2008;15:251-6.
4. Dinulovic D, Radonjic G. Diabetes mellitus/male infertility. *Arch Androl* 1990;25:277-93.
5. Permenter MG, Lewis JA, Jackson DA. Exposure to nickel,

- chromium, or cadmium causes distinct changes in the gene expression patterns of a rat liver derived cell line. *PLoS One* 2011;6:e27730.
6. Tikare SN, Das Gupta A, Dhundasi SA, Das KK. Effect of antioxidants L-ascorbic acid and alpha-tocopherol supplementation in nickel exposed hyperglycemic rats. *J Basic Clin Physiol Pharmacol* 2008;19:89-101.
7. Alvarez C, Bladé C, Cartaña J. Alpha 2-adrenergic blockade prevents hyperglycemia and hepatic glutathione depletion in nickel-injected rats. *Toxicol Appl Pharmacol* 1993;121:112-7.
8. Kadota I, Kurita M. Hyperglycemia and islet cell damage caused by nickelous chloride. *Metabolism* 1955;4:337-42.
9. Sies H. Antioxidant functions of vitamins. *Ann N Y Acad Sci* 1993;669:7-20.
10. Khan NH, Rahman M, Nur-e-Kamal MS. Antibacterial activity of *Euphorbia thymifolia* Linn. *Indian J Med Res* 1988;87:395-7.
11. Trinder P. Determination of blood glucose using an oxidase-peroxidase system with a non-carcinogenic chromogen. *J Clin Pathol* 1969;22:158-61.
12. Bordes E, Papillion VV. Myocardial change induced by nickel and in association with cadmium. *Rev Ig Bacteriol Virusal Parazitol Epidemiol Pneumotizol* 1983;32:51-6.
13. Canoru N, Üek R, Atamer A, Dursun M, Turgut C, Gnelü E, et al. Protective effects of vitamin E, selenium and allopurinol against stress-induced ulcer formation in rats. *Turk J Med Sci* 2001;31:199-203.
14. Venkataraman BV, Joseph T, Shetty PS, Stephen PM. Acetylcholine levels of rat brain and heart in starvation and protein restriction. *Indian J Physiol Pharmacol* 1984;28:223-6.
15. Chiamori N, Henry RJ. Study of the ferric chloride method for determination of total cholesterol and cholesterol esters. *Am J Clin Pathol* 1959;31:305-9.
16. Lowry OH, Rosebrough NJ, Farr AL, Randall RJ. Protein measurement with the Folin phenol reagent. *J Biol Chem* 1951;193:265-75.
17. Reitman S, Frankel S. A colorimetric method for the determination of serum glutamic oxalacetic and glutamic pyruvic transaminases. *Am J Clin Pathol* 1957;28:56-63.
18. Tietz NW. *Fundamentals of Clinical Chemistry*. Philadelphia: WB Saunders; 1970.
19. Moshage H, Kok B, Huizenga JR, Jansen PL. Nitrite and nitrate determinations in plasma: A critical evaluation. *Clin Chem* 1995;41:892-6.
20. Ohkawa H, Ohishi N, Yagi K. Assay for lipid peroxides in animal tissues by thiobarbituric acid reaction. *Anal Biochem* 1979;95:351-8.
21. Culling CF, Ellison RT, Barr WT. *Cellular Pathology Techniques*. 4<sup>th</sup> ed.. London: Butterworth and Co.; 1985.
22. Wiernsperger NF. Oxidative stress as a therapeutic target in diabetes: Revisiting the controversy. *Diabetes Metab* 2003;29:579-85.
23. Ebuehi OA, Ajuluchukwu AE, Afolabi OT, Akinwande AI. Oxidative stress in alloxan-induced diabetes in female and male rats. *Adv Med Dent Sci* 2009;3:71-5.
24. Izquierdo-Vega JA, Soto CA, Sanchez-Peña LC, De Vizcaya-Ruiz A, Del Razo LM. Diabetogenic effects and pancreatic oxidative damage in rats subchronically exposed to arsenite. *Toxicol Lett* 2006;160:135-42.
25. Vivek KS, Suresh K, Hitesh JP, Shivakumar H. Hypoglycemic activity of *Ficus glomerata* in alloxan induced diabetic rats. *Int J Pharma Sci* 2010;1:976-81.
26. Jargar JG, Dhundasi SA, Das KK. Influence of  $\alpha$ -tocopherol on blood glucose regulation of alloxan induced male diabetic rats exposed to nickel sulfate. *Biomedicine* 2014;34:296-303.
27. Pryor WA. Oxidative stress status-the fifth set *Free Radic Biol Med* 2000;29:1063.
28. Ozdemir O, Akalin PP, Baspinar N, Hatipoglu F. Pathological changes in the acute phase of streptozotocin induced diabetic rats. *Bull Vet Inst Pulawy* 2009;53:783-90.
29. Mallick C, Mandal S, Barik B, Bhattacharya A, Ghosh D. Protection of testicular dysfunctions by MTEC, a formulated herbal drug, in streptozotocin induced diabetic rat. *Biol*

- Pharm Bull 2007;30:84-90.
30. Dosoo DK, Rana SV, Offe-Amoyaw K, Tete-Donkor D, Maddy SQ. Total antioxidant status in non-insulin-dependent diabetes mellitus patients in Ghana. *West Afr J Med* 2001;20:184-6.
  31. Kristal-Boneh E, Collier D, Froom P, Harari G, Ribak J. The association between occupational lead exposure and serum cholesterol and lipoprotein levels. *Am J Public Health* 1999;89:1083-7.
  32. Reznick AZ, Packer L. Oxidative damage to proteins: Spectrophotometric method for carbonyl assay. *Methods Enzymol* 1994;233:357-63.
  33. Das KK, Dasgupta S. Alteration of testicular biochemistry during protein restriction in nickel treated rats. *Biol Trace Elem Res* 1997;60:243-9.
  34. Larcen A, Lambert H, Laprevote-Heully MC, Delorme N. Light and electron microscopic study of hepatic lesions in the course of hyperlactatemia in diabetic patients (author's transl). *Diabete Metab* 1979;5:103-12.
  35. El-Demerdash FM, Yousef MI, El-Naga NI. Biochemical study on the hypoglycemic effects of onion and garlic in alloxan-induced diabetic rats. *Food Chem Toxicol* 2005;43:57-63.
  36. Concepción Navarro M, Pilar Montilla M, Martín A, Jiménez J, Pilar Utrilla M. Free radical scavenger and antihepatotoxic activity of *Rosmarinus tomentosus*. *Planta Med* 1993;59:312-4.
  37. Belkina LM, Smirnova EA, Terekhina OL, Kruglov SV, Boichuk ES. Role of nitric oxide in the pathogenesis of alloxan diabetes. *Bull Exp Biol Med* 2013;154:602-5.
  38. Samarghandian S, Borji A, Delkhosh MB, Samini F. Safranal treatment improves hyperglycemia, hyperlipidemia and oxidative stress in streptozotocin-induced diabetic rats. *J Pharm Pharm Sci* 2013;16:352-62.
  39. Jargar JG, Yendigeri SM, Hattiwale SH, Dhundasi SA, Das KK. A-tocopherol ameliorates nickel induced testicular oxidative and nitrosative stress in albino rats. *J Basic Clin Physiol Pharmacol* 2012;23:77-82.
  40. Kawanishi S, Inoue S, Yamamoto K. Site-specific DNA damage induced by nickel (II) ion in the presence of hydrogen peroxide. *Carcinogenesis* 1989;10:2231-5.
  41. Sofikitis N, Takenaka M, Kanakas N, Papadopoulos H, Yamamoto Y, Drakakis P, *et al.* Effects of cotinine on sperm motility, membrane function, and fertilizing capacity *in vitro*. *Urol Res* 2000;28:370-5.
  42. Shrilatha B, Muralidhara. Occurrence of oxidative impairments, response of antioxidant defences and associated biochemical perturbations in male reproductive milieu in the Streptozotocin-diabetic rat. *Int J Androl* 2007;30:508-18.
  43. Kianifard D, Sadrkhanlou RA, Hasanzadeh S. The ultrastructural changes of the sertoli and leydig cells following streptozotocin induced diabetes. *Iran J Basic Med Sci* 2012;15:623-35.
  44. Sanguinetti RE, Ogawa K, Kurohmaru M, Hayashi Y. Ultrastructural changes in mouse Leydig cells after streptozotocin administration. *Exp Anim* 1995;44:71-3.
  45. Oztürk F, Gül M, Agkadir M, Yagmurca M. Histological alterations of rat testes in experimental diabetes. *T Kin J Med Sci* 2002;22:173-8.
  46. Johnson FC. The antioxidant vitamins. *CRC Crit Rev Food Sci Nutr* 1979;11:217-309.

**How to cite this article:** Jargar JG, Yendigeri S, Dhundasi SA, Das KK. Protective effect of Vitamin E (a-tocopherol) on nickel-induced alteration of testicular pathophysiology in alloxan-treated diabetic rats. *Int J Clin Exp Physiol* 2014;1:290-7.

**Source of Support:** Nil, **Conflict of Interest:** Nil.